


Reference Materials

The Istanbul Protocol: International Guidelines for the Investigation and Documentation of Torture

MEDICAL PHYSICAL EXAMINATION OF ALLEGED TORTURE VICTIMS

A Practical Guide to the Istanbul Protocol
– for Medical Doctors

2004



This guide was written by the International Rehabilitation Council for Torture Victims (IRCT) as part of the Istanbul Protocol Implementation Project, an initiative of Physicians for Human Rights USA (PHR USA), the Human Rights Foundation of Turkey (HRFT), the World Medical Association (WMA), and the International Rehabilitation Council for Torture Victims (IRCT)



© International Rehabilitation Council for Torture Victims (IRCT)
Borgergade 13
P.O. Box 9049
DK-1022 Copenhagen K
DENMARK
Tel: +45 33 76 06 00
Fax: +45 33 76 05 00
E-mail: irct@irct.org
<http://www.irct.org>

ISBN 87-88882-71-3

The Istanbul Protocol: International Guidelines for the
Investigation and Documentation of Torture

MEDICAL PHYSICAL EXAMINATION OF ALLEGED
TORTURE VICTIMS

A Practical Guide to the Istanbul Protocol
- for Medical Doctors

Ole Vedel Rasmussen, MD, DMSc

Stine Amris, MD

Margriet Blaauw, MD, MIH

Lis Danielsen, MD, DMSc

REFERENCE MATERIALS REGARDING THE USE OF THE ISTANBUL PROTOCOL: INTERNATIONAL GUIDELINES FOR THE INVESTIGATION AND DOCUMENTATION OF TORTURE

The Istanbul Protocol is the first set of international guidelines for the investigation and documentation of torture. The Protocol provides comprehensive, practical guidelines for the assessment of persons who allege torture and ill-treatment, for investigating cases of alleged torture, and for reporting the findings to the relevant authorities. Initiated and co-ordinated by Physicians for Human Rights USA (PHR USA) and Action for Torture Survivors and the Human Rights Foundation of Turkey (HRFT), the Protocol was developed over three years with the involvement of more than 40 organisations, including the International Rehabilitation Council for Torture Victims (IRCT) and the World Medical Association (WMA).

With the generous support of the EU, the 'Istanbul Protocol Implementation Project' was carried out between March 2003 and March 2005 to increase awareness, national endorsement and tangible implementation of the Protocol in five target countries: Georgia, Mexico, Morocco, Sri Lanka and Uganda.

The resource materials presented here were developed as a source of practical reference for health and legal professionals during the trainings conducted as part of the project. The materials were widely disseminated to the 250 individual health professionals and 125 lawyers who participated in the trainings and were also distributed to relevant national institutions and government agencies in the five countries. It is hoped that these materials offer insights and create synergy between the two professions in a joint effort to combat torture.

INDEX

| | |
|---|-----------|
| PREAMBLE | 1 |
| Purpose and contents of this manual | 1 |
| INTRODUCTION | 3 |
| MEDICAL CERTIFICATE | 3 |
| PITFALLS | 4 |
| References | 4 |
| PART 1: DERMATOLOGICAL FINDINGS AFTER ALLEGED TORTURE | 5 |
| Macroscopic changes | 5 |
| Description of skin lesions | 6 |
| Blunt trauma | 6 |
| Sharp trauma | 8 |
| Thermal injuries | 8 |
| Corrosive injuries | 9 |
| Electrical injuries | 9 |
| Skin diseases | 11 |
| Microscopic changes | 11 |
| References | 12 |
| PART 2: THE MUSCULO-SKELETAL SYSTEM | 14 |
| Possible lesions in the musculo-skeletal system after physical torture | 16 |
| Soft tissue injuries | 16 |
| Muscle tone | 16 |
| Stretch range of movement | 17 |
| Tender and trigger points | 17 |
| Musculo-tendinous inflammation | 17 |
| Ligaments injuries | 17 |
| Bone injuries | 18 |
| Possible lesions and assessment of the musculo-skeletal system following specific forms of physical torture | 19 |
| Suspension by the arms | 19 |
| Acute symptoms and signs | 20 |
| Symptoms and signs in the chronic phase | 20 |
| Clinical examination | 21 |
| Falanga | 21 |
| Acute symptoms and signs | 21 |
| Symptoms and signs in the chronic phase | 21 |
| Theories explaining the persistent pain and foot dysfunction after falanga | 22 |
| Reduced shock absorbency in the heel pads | 22 |
| Changes in the plantar fascia | 22 |
| Closed compartment syndrome | 22 |
| Neurogenic pain | 23 |
| Impaired walking | 23 |
| Clinical examination | 23 |
| Neurological | 24 |
| References | 25 |
| PART 3: CARDIOPULMONARY | 26 |
| Gastrointestinal | 26 |
| Urological | 27 |
| Otorhinolaryngological | 28 |
| Ophthalmological | 28 |
| References | 28 |
| PART 4: GYNAECOLOGICAL EXAMINATION | 30 |
| PART 5: EXAMINATION OF CHILDREN ¹ | 32 |
| References | 32 |
| Full list of references | 34 |
| Legends to figures in the Medical Physical Training Manual | 37 |

PREAMBLE

Torture is one of the most inhumane acts an individual can inflict on another. Although torture is prohibited under international law, it takes place in many countries worldwide.

The Istanbul Protocol, which was developed over three years by around 40 experts in forensic science and human rights, provides comprehensive, practical guidelines for the assessment of persons who allege torture, and ill-treatment, for investigating cases of alleged torture, and for reporting the findings to the relevant authorities.

The Istanbul Protocol was submitted to the UN High Commissioner for Human Rights on 9 August 1999. The Istanbul Principles have subsequently been endorsed in resolutions of the Human Rights Commission and the General Assembly, and the Protocol has been published by the Office of the High Commissioner for Human Rights in its Professional Training Series.

In spite of its international standing among legal, health, and human rights experts, awareness of the Istanbul Protocol is still relatively limited. In many cases, medical and legal university curricula do not provide instruction on the examination of torture victims, the treatment of torture victims, or the consequences of torture. As a result, many health and legal professionals have little or no training in the investigation and documentation of torture, which requires specific technical skills and knowledge on both medical and legal procedures to be conducted effectively.

Purpose and contents of this guide

The purpose of this guide is to facilitate the work of health and legal professionals with the implementation of the Istanbul Protocol. Not all aspects of examination of alleged victims of torture are elaborated on. This guide does not replace the Istanbul Protocol. It should be used together with the Istanbul Protocol.

As in the Istanbul Protocol, torture is defined in this guide according to the definition of torture in article 1 of the UN Convention against Torture (UNCAT):

“For the purpose of this Convention, the term “torture” means any act by which severe pain or suffering, whether physical or mental, is intentionally inflicted on a person for such purposes as obtaining from him or from a third person information or a confession, punishing him for an act he or the third person has committed or is suspected of having committed, or intimidating or coercing him or a third person, or for any reason based on discrimination of any kind, when such pain or suffering is inflicted by or at the instigation of or with the consent or acquiescence of a public official or other person acting in an official capacity. It does not include pain or suffering arising only from, inherent in or incidental to lawful sanctions. “

The guide describes the Medical Physical examination and physical symptoms in connection with torture.

It emphasises the importance of the medical certificate. It is divided into several sections. Each section refers to the relevant paragraph and chapter in the Istanbul Protocol.

Especially the sections on dermatological findings and symptoms related to the musculo-skeletal system are elaborated on in this part. The text on the dermatological findings after alleged torture is also available on CD-ROM, with photographs and figures supporting the text. Symptoms related to the musculo-skeletal system are the most frequently reported physical complaints.

Although the findings and symptoms of the musculo-skeletal systems are in later stages in general unspecific, they are important to support the history of torture. It should be noticed that “The distinction between physical and psychological torture methods is artificial. For example, sexual torture causes both physical and psychological symptoms, even when there has been no physical assault” (Istanbul Protocol §144)

This guide should be used in conjunction with two separate documents: one on psychological evidence of torture and one designed for legal professionals.

A CD-ROM has been developed in addition to this guide. The CD-ROM provides pictures of torture methods, torture instruments, and microscopic and microscopic evidence.

INTRODUCTION

Physical examination in connection with torture and other related human rights violations may have two purposes:

1. Documentation of torture allegations.
2. Treatment of health problems.

This manual will focus on the first purpose.

In this chapter, acute and chronic somatic consequences of torture will be described for the different organ systems.

A physical examination with regard to health problems cannot stand alone; it should be combined with psychological and psychiatric examinations, as well as an evaluation of social functioning.

MEDICAL CERTIFICATE

When a doctor writes a certificate after a medical examination of a person who alleges having been tortured, it is extremely important that the doctor states the degree of consistency with the history of torture.

A conclusion indicating the degree of support to the alleged history of torture should be based on a discussion of possible differential diagnoses (non-torture-related injuries – including self-inflicted injuries – and diseases).

The degree of support should be indicated as follows:

1. High degree of support
2. Consistent with the alleged torture, moderate degree of support
3. Consistent with the alleged torture, slight degree of support
4. The changes cannot support the history of torture

Different physical torture methods leave different physical sequelae. Therefore, a very important part of the physical examination is obtaining a detailed account of the alleged torture methods to which the person has been subjected. Many torture victims may have problems recalling the exact details of their torture, and sometimes give conflicting stories during repeated interviews.

It is also important to take into account that mental problems may have serious health implications. Prolonged stress conditions have in many studies shown to have somatic consequences via neuro-humeral and other mechanisms.

(Please see § 160-161, § 167-168 and §186-187)

PITFALLS

As highlighted in the beginning of this section, history-taking is the crucial element in the medical evaluation of a refugee who alleges having been tortured. With regard to this, there are three major possible pitfalls:

1. Victims might not always relate what they have been through,
2. What victims relate might not always be the truth, and finally
3. They may not be aware of the time of appearance of a non-torture-related disease, and may therefore wrongly suggest its relation to torture.

The following case story by Jakobsson (1991) illustrates the first possibility very well:

"A 20-year-old woman from a Middle Eastern country walked in the street without a veil, and with lipstick and painted nails. She was taken by the "chastity police". At the station, she was raped by policemen, and her right hand was put into a meat grinder. She received surgical treatment after some time, but lost three fingers. She arrived in Sweden with her right hand hidden in her sleeve, and did not show her injuries to the police, nor to the lawyer. She was refused asylum. After showing the evidence, she was granted asylum a short time after her appeal.

This case shows that it is sometimes difficult for torture victims to be taken seriously, and to show and talk about their injuries."

References

Jakobsson, S. W. (1991). Brett samarbete nödvändigt för diagnostik och behandling av tortyrskador. *Läkartidningen*, 88, 4261-4264.

PART 1: DERMATOLOGICAL FINDINGS

AFTER ALLEGED TORTURE

MACROSCOPIC CHANGES

The significance of skin lesions is mostly related to the documentation of a history of torture. Acute lesions may give health problems, e.g. pain and secondary infections, including problems with healing, especially when they are located in an area with venous or arterial insufficiency.

Scars located close to a joint may induce contracture, decreased mobility of the joint and pain during activity.

Apart from this, scars seldom inconvenience the patient, although they may sometimes be of cosmetic importance, since they may be a reminder of the torture and add to the changed sense of identity induced by torture.

A detailed history of the alleged torture and the related symptoms it has induced is important in order to evaluate the significance of the observed lesions on the skin.

Information about the position of the victim and of the torturer during the torture is particularly important, as well as information about the shape of instruments in contact with the skin. In cases with no or uncharacteristic lesions, a characteristic history may be the only support to the allegation of torture, as e.g. in some cases of electrical torture.

Also a history of skin diseases and non-torture-related lesions are of importance.

The examination should include the entire body surface to detect signs of:

1. Skin diseases
2. Non-torture-related lesions
3. Torture-related lesions

Torture sequelae related to the skin may be:

1. Lesions resulting from direct physical injuries
2. The occurrence of new – or aggravation of existent – skin diseases, provoked by physical or psychological trauma.

When a doctor writes a certificate after conducting a medical examination of a person who alleges having been tortured, it is extremely important that the doctor states the degree of

consistency with the history of torture (*Allden et al., 2001*). A conclusion indicating the degree of support to the alleged history of torture should be based on a discussion of possible differential diagnoses (non-torture-related injuries – including self-inflicted injuries – and skin diseases).

The degree of support should be indicated as follows:

1. A high degree of support
2. Consistent with the alleged torture, moderate degree of support
2. Consistent with the alleged torture, slight degree of support
4. The changes cannot support the history of torture

Acute lesions are often characteristic since they show a pattern of inflicted injury that differs from non-inflicted injuries, e.g. by their shape and distribution on the body. Since most lesions heal within a short period of time, leaving no or non-specific scars, a characteristic history of the acute lesions is important. Also a history of the development until healing is of importance.

Description of skin lesions

Description of skin lesions should include the following points:

1. Localisation (use body diagram): symmetrical, asymmetrical
2. Shape: round, oval, linear, etc.
3. Size: (use ruler)
4. Colour
5. Surface: scaly, crusty, ulcerative, bullous, necrotic
6. Periphery: regular or irregular, zone in the periphery
7. Demarcation: sharply, poorly
8. Level in relation to surrounding skin: atrophic, hypertrophic, plane

The following findings are supportive of external infliction:

1. Lack of symmetry (may also be the case for some skin diseases)
2. Linear lesions in irregular or criss-cross arrangements
3. A linear zone extending circularly around an extremity
4. A regular, narrow, hyperpigmented or hypertrophic zone surrounding a scar (sequels to an inflammatory zone around a necrotic area), (may also be the case with skin diseases with necrotic areas, e.g. necrotic vasculitis)

Blunt trauma

Blunt trauma may leave ecchymoses, contusions or lacerations with extravasation of blood in the skin and subcutaneous tissue, in some cases reflecting the shape of the instrument used, e.g. from beating with a stick (*Rasmussen, 1990*).

Two parallel linear lesions (“tramline bruises”) result from a blow with a rod or stick (Knight, 1991a). The haemorrhagic areas often move down the body during the following days. Deep tissue bruises might not be seen on the surface. The lesions change colour from dark red, to dusky purple, to brown, to green, to yellow and to hyperpigmented brown, or they disappear.

Severe beating on the soles of the feet, “Falanga”, may leave contusions in the arch of the feet and swelling of the feet extending from the arch to the medial aspects of the feet and ankles (Bro-Rasmussen and Rasmussen, 1978).

Blunt trauma often leaves no or uncharacteristic scars (Cohn et al., 1978). Flogging or beating with canes or truncheons may, however, leave characteristic scars, e.g. asymmetric, linear, straight or curved or “tramline”-shaped scars, showing a pattern of external infliction (Danielsen, 1992; Petersen & Rasmussen, 1992; Forrest 1999). The scars may be hypertrophic with a narrow, regular, hyperpigmented area in the periphery, representing “arrowline” bruises or an inflammatory zone appearing around necrotic tissue in the acute phase (Fig. 1) (Danielsen, 1992).

≠ A differential diagnosis could be plant dermatitis, usually dominated, however, by shorter scars, with a narrow zone of hyperpigmentation in the periphery.

In one case, the alleged torture was beating and scalding on the back. Symmetrical, atrophic, depigmented, linear changes typical for striae distensae were observed on the back and in both axillary regions (Fig. 2) (Danielsen, 1992). **The skin changes could not support the history of torture.** The patient, however, may have been unaware of the changes on the back before the torture.

Prolonged application of tight ligatures may leave a linear zone extending circularly around the arm or leg, in one case with lack of hair indicating cicatricial alopecia (Danielsen and Berger, 1981).

≠ No differential diagnosis in the form of a spontaneous skin disease exists because of the location of the scar.

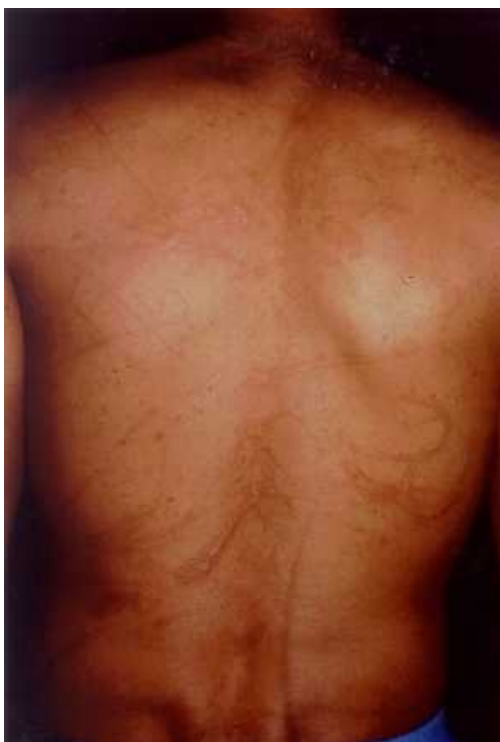
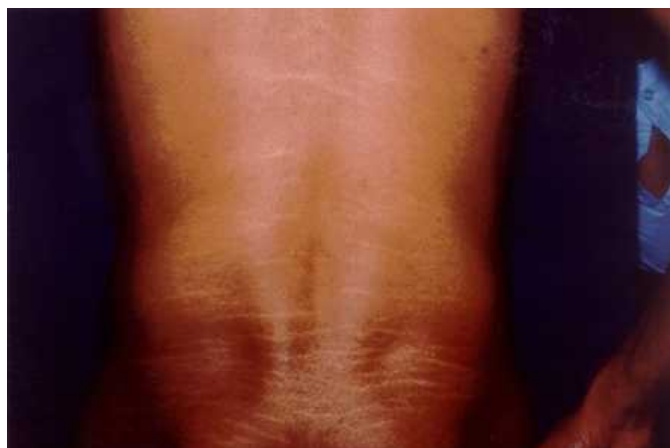
Figure 1. Long, straight or curved, linear scars in an asymmetric pattern on the back (Danielsen, 1992). Published with kind permission from Torture.

Figure 2. Symmetrical, atrophic, depigmented, linear changes on the back typical of striae distensae (Danielsen, 1992). Published with kind permission from Torture.



Sharp trauma

Sharp trauma, e.g. caused by the use of a razor blade, knife or bayonet, gives characteristic ulcers and usually leaves recognisable scars. In some cases, self-infliction should be considered, particularly when located on a wrist (*Danielsen, 1992, Petersen & Rasmussen, 1992*). If pepper is applied to the open wounds, the scars may become hypertrophic (*Danielsen, 1992*).

≠ A differential diagnosis could be traditional healers, African ritual scar-tattoos or art on the body (*Nancke-Krogh, 1985*).

In one case, where the deepness of a scar, allegedly following the use of a sword, was doubted, the use of a high-frequency ultrasound could demonstrate a considerable, deep scar (*Gniadecka & Danielsen, 1995*). Afterwards, the patient was granted refugee status.

Thermal injuries

Burning with cigarettes, hot instruments or hot fluids leaves acute burns of varying degrees. Burning is the form of torture that most frequently leaves scars, often of diagnostic value.

Cigarette burns often leave 5-10 mm large, circular and macular scars with a depigmented centre and a hyperpigmented, relatively indistinct periphery (*Kjærsgård and Genefke, 1977*).

≠ Dermatological conditions, e.g. sequels to pustules, might be a differential diagnosis.

Burning via the transfer of larger amounts of energy to the skin than that transferred when stubbing a cigarette on the skin often produces markedly atrophic scars. They present a narrow, regular, hyperpigmented or hypertrophic periphery, originating from the inflammatory zone, which surrounds the necrotic tissue in the acute phase (*Danielsen, 1982*). While their shape reflects the shape of the instrument used, their size relates to the amount of energy transferred to the skin.

Following alleged torture from burning on several areas of the skin with a heated, circular metal rod, the size of a cigarette, mostly circular scars with an atrophic centre and a regular, narrow, hyperpigmented or hypertrophic zone in the periphery were observed. Their diameter varied from below 1 cm to around 2 cm, and the patient had 35 scars distributed on several areas of the skin (*Danielsen and Berger, 1981*).

≠ A differential diagnosis could be sequels to abscesses, but such scars usually do not show the typical, narrow zone in the periphery (*Petersen & Rasmussen, 1992*).

Burning material from a rubber tyre, placed above the head of a woman, running down on her head and body, left keloid changes on the central area of her chest (the medial areas of her breasts not included). The periphery of the scar was irregular and demarcated via a narrow, well-defined zone of hyperpigmentation, and its shape corresponded to damage caused by material running down the body (*Rasmussen, 1990*).

A scar following alleged torture from burning with a glowing metal rod placed across the broad area of the calf was primarily suggested to represent changes induced by venous insufficiency. The scar was shaped like a boat, and was placed across the broad part of the calf; it had an atrophic centre and a regular, narrow zone of hyperpigmentation in the periphery (*Fig. 3*) (*Danielsen, 1995*). The shape of the scar thus corresponds to a lesion induced by a rod pressed against the soft calf, and the appearance of the scar to a third degree burn because of its atrophic centre and the narrow hyperpigmented zone in its periphery.

≠ In contrast, venous insufficiency leaves indistinctly limited hyperpigmentation and scars from ulcers located distally on the lower leg (Fig. 4) (Danielsen, 1995).

Afterwards, the patient was granted refugee status.

When *the nail matrix is burnt*, subsequent growth produces striped, thin, deformed nails, sometimes broken up in longitudinal segments. If *the nail is also pulled off*, an overgrowth of tissue may occur from the proximal nail fold (Danielsen, 1992).

≠ Changes caused by lichen planus may be a relevant differential diagnosis, while fungus infection is characterised by thickened, yellowish, crumbling nails, different from those mentioned above.

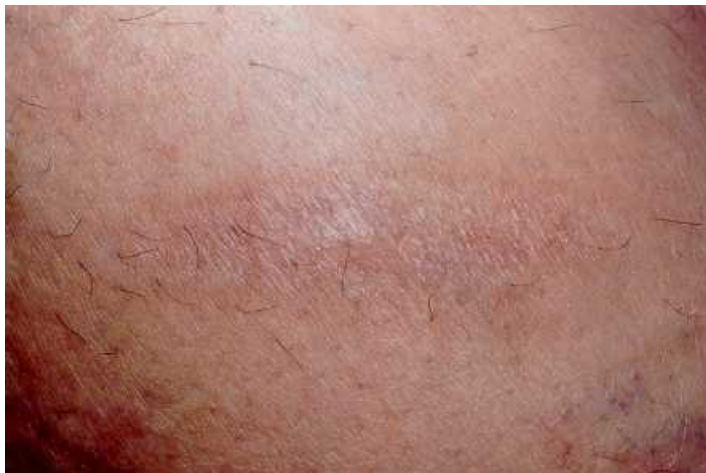

Figure 3. A scar shaped like a boat, placed across the calf with an atrophic centre and a narrow, regular zone of hyperpigmentation in the periphery (Danielsen, 1995). Published with kind permission from Sår.

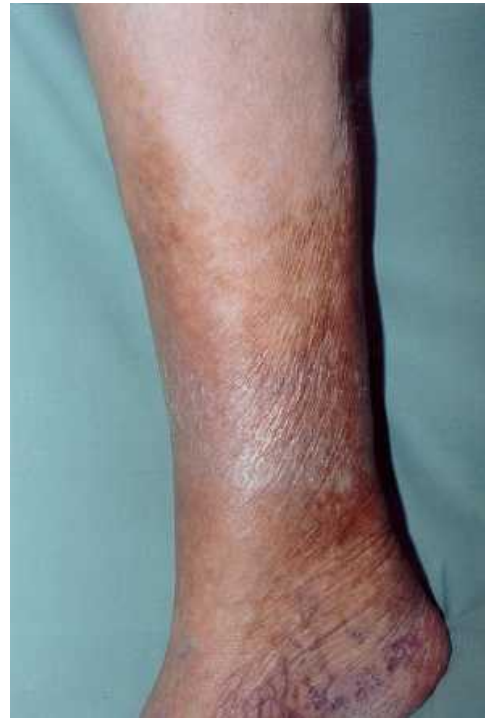

Figure 4. Venous insufficiency with indistinctly limited hyperpigmentation distally on the lower leg (Danielsen, 1995). Published with kind permission from Sår.

Corrosive injuries

Corrosive injuries, caused by acid thrown against a victim, caused linear scars, a few cm wide, with a depigmented centre and a regular, narrow, hyperpigmented zone in the periphery, located on the thighs and buttocks (Gordon and Mant, 1984). They were arranged in an asymmetric pattern, mostly obliquely directed down the legs. They showed signs of external infliction in agreement with a liquid running down the legs, and they indicated sequels to necrotic areas as expected following a corrosive injury.

Electrical injuries

Electric current follows the shortest route between the two electrodes through tissue with the lowest resistance, i.e. blood vessels, nerves and muscles (Danielsen, 2002). When using high-voltage stun weapons, the current flow cannot, however, be limited to the pathway between the electrodes (Amnesty International, 1999).

The possibility of finding signs of electrical influence in the skin, particularly histological signs, is related to the type of electricity transferred, since the electrolytic action will be most pronounced by transfer of direct current and will not be present following transfer of high-frequency alternating current, where the concomitant heat generation dominates (Danielsen, 2002). Also, the amount of

energy used plays a role for a domination of burn injuries in the lesions, particularly concerning low frequency alternating current.

In some of the cases, electric torture leaves acute lesions on the skin. Unlike burn lesions, these lesions usually **do not** reflect the shape of the instrument used, but appear in segments within the influenced areas, since the current selects areas with low resistance (*Dyhre-Poulsen et al., 1977, Danielsen et al., 1978, Danielsen et al., 1978*).

Electrical torture via electrodes shaped like a knitting needle, "Picana", leaves clusters and linear arrangements of 1-5 mm wide lesions, covered by red-brown crusts, sometimes surrounded by a 1-2 mm broad, erythematous zone with irregular and indistinct edges (*Rasmussen, 1990*). Lesions in lines following a linear application of the electrodes may also be seen. The crusts probably correspond to an electrical injury and may contain deposits of metal from the electrodes (*Thomsen, 1984; Jacobsen, 1997*). The concomitant heat development has not been sufficient to induce a regular inflammation in the periphery.

≠ Differential diagnosis may be insect bites or scratching.

Many, a few mm large, red lesions have been seen following the use of a battery-driven electrical instrument (TAT-Group against Torture 2001).

≠ A contact dermatitis may be a differential diagnosis.

Well-demarcated, serpiginous lesions, measuring 1-2 cm across, with an irregular, narrow, elevated, peripheral zone and a central area containing several black spots, each measuring 1-2 mm, have been observed shortly after electrical injuries on the left side of the chest and on the left arm (*Danielsen et al., 1991*). The lesions show indication of electrical injury because of their appearance in 1-2 mm large segments and because of the involvement of blood vessels.

≠ Vasculitis or haemorrhagic herpes zoster might constitute a differential diagnosis. The location might be helpful since vasculitis is chiefly located at the lower extremities, is symmetrical and is sometimes more diffusely located, while herpes zoster is located in an area innervated by a single ganglion and is unilateral.

Clusters of round, red macular scars, about 1 mm in diameter, have been observed four weeks after "Picana" (*Kjærsgaard and Genefke, 1977*). Eight weeks later, many of the scars had disappeared. The remaining scars were small, white or red-brown spots.

≠ Among the skin diseases leaving pigmented scars is lichen planus leaving about 2 mm large scars.

≠ Electrical torture has been reported to induce 6-8 mm large, irregular, red-brown, keloid scars on the helix of both ears (*Bork & Nagel, 1997*).

≠ Differential diagnosis might be a chondrodermatitis helicis, but this is usually covered by a scale, and is pale and painful.

Six months after the use of a 45 cm long stun gun, delivering 150,000 V, with a screw 4 mm in diameter at its end and 12 small places from which electricity is also emitted from the lower part of its side, a sharply demarcated bluish line 1 mm across, forming a complete circle 5 mm in diameter and a second mark of similar characteristics completing only two-thirds of a circle, were observed (*European Committee for the Prevention of Torture, 1998*).

≠ Similar fractions of a narrow red ring appearing in segments have been seen in the days after defibrillation using 2736 V along the periphery of the pad (*Danielsen et al., 2003*). They have been found to be due to a high current density under the perimeter of the electrodes.

Skin diseases

An example of a skin disease being psychologically provoked by torture may be the concomitant occurrence of an urticarial eruption. Physically provoked skin diseases may be the development of psoriasis or lichen planus in the traumatised area, as a “Koebner reaction” (Danielsen, 1992). However, such skin changes have little diagnostic significance in relation to torture.

MICROSCOPIC CHANGES

If a victim agrees, a 3-4 mm punch biopsy, under local anaesthesia, might be helpful in supporting an allegation of electrical torture (Danielsen et al., 1978; Danielsen et al., 1978, Thomsen et al., 1983; Karlsmark et al., 1984, Karlsmark et al., 1988; Danielsen et al., 2003; Thomsen, 1984; Karlsmark, 1990).

Previously, only few cases of electrical torture have been studied histologically (Danielsen et al., 1991; Öztop, Lök, Baykal and Tunca, 1994; Danielsen, Karlsmark and Thomsen, 1997; TAT-Group against Torture, 2001).

Only in one case, in which lesions were excised seven days after the injury, were alterations in the skin diagnostic of electrical injuries observed (deposition of calcium salts on dermal fibres in viable tissue located around necrotic tissue at the surface and on collagen fibres deep in the dermis).

Lesions excised a few days after the alleged electric torture showed segmental changes and deposits of calcium salts on cellular structures, consistent with the influence of an electric current, but with only a moderate degree of support.

A biopsy taken one month after the alleged electrical torture showed a conical scar, 1-2 mm broad, with an increased number of fibroblasts and tightly packed, thin collagen fibres arranged in parallel to the surface, consistent with electrical injury, but with only a slight degree of support.

A biopsy taken five days after alleged electrical torture via the use of a battery-driven electrical instrument, probably delivering high-frequency alternating current, where the concomitant heat development dominates, showed non-specific alterations with subepidermal bullae consistent with thermal injuries.

≠ Toxic contact dermatitis could be a differential diagnosis, the support to the history of torture being of a slight degree.

Even if an examination does not reveal any abnormal findings, the possible use of electrical torture cannot be excluded..

The use of high-frequency ultrasound may be helpful in discovering the location of calcium deposits in order to select an area for biopsy (Danielsen, 2002)

(For more information refer to Chapter V, sections C.1, D.1 and D.5 of the Istanbul Protocol)

References

- Allden, K., Baykal, T., Iacopino, V., Kirschner, R., Özkalıpci, Ö., Peel, M., et al. (Eds.). 2001). Istanbul Protocol: Manual on the effective investigation and documentation of torture and other cruel, inhuman or degrading treatment or punishment. Geneva, Switzerland: United Nations. Office of the High Commissioner for Human Rights.
- Amnesty International. (1999). USA - cruelty in control?: The stun belt and other electro-shock equipment in law enforcement. (AI Index AMR 51/54/99). London: Author
- Bork, K., & Nagel, C. (1997). Long-standing pigmented keloid of the ears induced by electrical torture. *Journal of the American Academy of Dermatology*, 36, 490-491
- Bro-Rasmussen, F., & Rasmussen, O. V. (1978). Falanga tortur. *Ugeskrift for Læger*, 140, 3197-3202.
- Cohn, J, Jensen, R, Severin, B, Stadler, H. (1978). Torture in the Argentine, Syria and Zansibar, *Ugeskr Læger*, 140, 3202-3206.
- Danielsen, L (1982). Hudforandringer efter tortur [Skin changes following torture]. *Måndesskrift for praktisk lægegerning*, 193-209.
- Danielsen, L. (1992). Skin changes after torture. In H. Marcussen and O.V. Rasmussen (Eds). *Examining Torture Survivors. Danish Medical Group, Amnesty International: Articles and guidelines: A reference book. Torture (Suppl. 1)*, 27-32
- Danielsen, L. (1995). Hudforandringer efter tortur [Skin changes following torture]. *Sår*, 3, 80-83.
- Danielsen, L. (2002). The examination and investigation of electric shock injuries. In M. Peel, & V. Iacopino (Eds.), *The medical documentation of torture* (pp. 191-205). London: Greenwich Medical Media
- Danielsen, L, Berger, P (1981). Torture sequelae located to the skin. *Acta Dermatovener (Stockh)* 61, 43-46.
- Danielsen, L, Genefke, I.K., Karlsmark, T, Lorenzen, S, Nielsen, K.G., Nielsen, O, Thomsen, HK, Aalund, O (1978). Termiske og elektriske skader i svinehud [Thermic and electric damages in pig skin], 140, 3191-3197.
- Danielsen, L., Gniadecka, M., Thomsen, H. K., Pedersen, F., Strange, S., Nielsen, K. G., Petersen, H.D. (2003). Skin changes following defibrillation. The effect of high voltage direct current. *Forensic Science International*, 134, 134-141.
- Danielsen, L., Karlsmark, T., & Thomsen, H. K. (1997). Diagnosis of skin lesions following electrical torture. *Romanian Journal of Legal Medicine*, 5, 15-20.
- Danielsen, L., Karlsmark, T., Thomsen, H. K., Thomsen, J. L., & Balding, L.E. (1991). Diagnosis of electrical skin injuries: A review and a description of a case. *American Journal of Forensic Medicine and Pathology*, 12, 222-226.
- Danielsen, L, Thomsen, HK, Nielsen, O, Aalund, O, Nielsen, K.G., Karlsmark, T, Genefke, I.K. (1978) Electrical and thermal injuries in pig skin. Evaluated and compared by light microscopy. *Forensic Science International*, 12, 211-225.
- Dyhre-Poulsen, P, Rasmussen, L, Rasmussen, OV (1977). Undersøgelser af et instrument til elektrisk tortur. [Investigation of an instrument of electrical torture]. *Ugeskrift for Læger*, 139, 1054-1056.
- European Committee for the Prevention of Torture (CPT). (1998). Report to the Government of the Netherlands on the visit to the Netherlands Antilles. Strassbourg, France: Author.
- Forrest, D. M. (1999). Examination for the late physical after effects of torture. *Journal of Clinical Forensic Medicine*, 6, 4-13.
- Gniadecka, M., & Danielsen, L. (1995). High-frequency ultrasound for torture-inflicted skin lesions. *Acta Dermato-Venereologica*, 75, 375-376.
- Gordon, E, Mant, A K (1984). Clinical evidence of torture. Examination of a teacher from El Salvador. *Lancet* ,I, 213-214.
- Jacobsen, H. (1997). Electrically induced deposition of metal on the human skin. *Forensic Science International*, 90, 85-92.

- Karlsmark, T. (1990). Electrically induced dermal changes: A morphological study of porcine skin after transfer of low-moderate amounts of electrical energy. [Doctoral Dissertation, University of Copenhagen, Denmark.] Danish Medical Bulletin, 37, 507-520.
- Karlsmark, T, Danielsen, L, Aalund, O, Thomsen, HK, Nielsen, O, Nielsen, KG, Lyon, H, Ammitzbøll, T, Møller, R, Genefke, IK. (1988). Electrically-induced collagen calcification in pig skin. A histopathologic and histochemical study. Forensic Sci Int, 39, 163-174
- Karlsmark, T, Thomsen, HK, Danielsen, L, Aalund, O, Nielsen, O, Nielsen, KG, Genefke, IK. (1984) Tracing the use of electrical torture. American Journal of Forensic Medicine and Pathology, 5, 333-337.
- Kjærsgaard, Aa R, Genefke, I K, (1977). Torture in Uruguay and Argentina. Ugeskrift for Læger, 139, 1057-1059.
- Knight, B (1991a). The pathology of wounds. In B. Knight, Forensic Pathology (pp 123-156). London: Arnold.
- Nancke-Krogh, S, (1985). Kunsten på kroppen [The art on the body]. Copenhagen.
- Petersen, H. D., & Rasmussen, O.V. (1992). Medical appraisal of allegations of torture and the involvement of doctors in torture. Forensic Science International, 53, 97-116.
- Rasmussen, O. V. (1990). Medical aspects of torture [Doctoral dissertation, University of Copenhagen, Denmark]. Danish Medical Bulletin, 37 (Suppl. 1).
- TAT-Group against Torture (2001) Torture in Basque Country, Report 2001. Gipuzkoa, Spain.
- Thomsen, H. K. (1984). Electrically induced epidermal changes. A morphological study of porcine skin after transfer of low-moderate amounts of electrical energy. [Doctoral dissertation, University of Copenhagen, Denmark]. Copenhagen, Denmark: FADL.
- Thomsen, H.K, Danielsen, L, Nielsen, O, Aalund, O, Nielsen, K.G., Karlsmark, T, Genefke, I.K, Christoffersen, P. (1983). The effect of direct current, sodium hydroxide and hydrochloric acid on pig epidermis. Acta pathologica.microbiologica immunologica scandinavia, Sect. A, 91, 307-316.
- Öztop, F., Lök, V., Baykal, T., & Tunca, M. (1994). Signs of electrical torture on the skin. Human Rights Foundation of Turkey. Treatment and Rehabilitation Centers report, 11, 97-104.

PART 2: THE MUSCULO-SKELETAL SYSTEM

Symptoms related to the musculo-skeletal system are the most frequently reported physical complaints at the time of torture, as well as at later stages. The associated signs and symptoms in the acute phase are similar to those following other types of acute traumas causing lesions in soft tissues (muscles, joint capsules, tendons, ligaments, nerves and vessels) and distortion/dislocation of joints and fractures (*Rasmussen, 1990; Forrest, 1999, 2002*).

Pain is the dominant symptom in relation to the musculo-skeletal system in the chronic phase. The clinical picture is one of localised or diffuse pain in muscles, joint pain, pain related to the spine and pelvic girdle, and neurological complaints mainly in the form of sensory disturbances and irradiating pain (*Rasmussen, 1990; Edston, 1999; Moreno & Grodin, 2002*).

Typical findings in the musculo-skeletal system in the chronic phase are:

- Increased muscle tone
- Tender and trigger points, especially in the muscles of the neck and shoulder girdle, muscles in the low back and pelvic girdle, and muscles of the lower extremities; tendinitis around the shoulder joint, elbow, knee and ankle joint
- Tenderness and restricted range of movement in peripheral joints, cervical and lumbar spine
- Tenderness in the soles and a compensatory altered gait (*Rasmussen, 1990; Skylv, 1992; Forrest 2002*)

The clinical examination of the musculo-skeletal system may be done:

1. in order to document findings consistent with allegation of torture, and/or
2. for the purpose of rehabilitation.

In documenting torture, the focus is on a description of signs supporting the use of torture, whereas in assessment for the purpose of rehabilitation, the focus should be on function and possibilities for interventions aiming at increasing function. In both instances, examination of the musculo-skeletal system is time-consuming. Most often, torture victims present widespread symptoms necessitating a thorough examination of many structures guided by the medical history; and knowledge about torture and applied torture methods is a prerequisite for the examination.

Assessment of the musculo-skeletal system should in general include:

- Examination of muscles and tendons: inspection, palpation (tone, stretch range, tenderness, changes in tissue texture) and assessment of function (strength, endurance)
- Examination of peripheral joints and bones: inspection, palpation and assessment of joint function (range of movement and stability)
- Examination of the spine and pelvic girdle: inspection, palpation and range of movement in the cervical, thoracic and lumbar spine
- Neurological examination: muscle strength, tendon reflexes, and sensibility

Some symptoms/symptom constellations may be related to the use of specific torture methods, e.g. pain in the feet and lower legs, and impaired walking after falanga (*Rasmussen 1990*), but symptoms

and findings in the musculo-skeletal system in the later stages are in general unspecific and cannot – on their own – document exposure to torture.

(See §183 in the Istanbul Protocol)

POSSIBLE LESIONS IN THE MUSCULO-SKELETAL SYSTEM AFTER PHYSICAL TORTURE

Soft tissue injuries

An acute stretch of a muscle may cause a partial or even complete tear of the muscle-tendon unit. These injuries are usually designated as stretch-induced injuries or muscle strains. A direct, non-penetrating blow to the muscle belly is another common mechanism for muscle injuries. Such muscle contusions may cause significant damage to the structure and function of the muscle.

The initial pathology shows many similarities in strains and contusions.

- Immediately following the injury, there is disruption of the architecture due to ruptured muscle fibres, as well as injury to the connective tissue framework and haematoma formation.
- Within two-three days, an intense inflammatory response develops. Pain and disability in the acute phase are – at least in part – due to this inflammation, and biomechanically the muscle is most impaired at this point.
- Within the first week, evidence of muscle regeneration may be found. Regenerating muscle cells and fibroblasts mounting a scar response are seen in the injured area. The combined regenerative and scar response results in a healed muscle that has fewer and smaller muscle fibres in the injured area, as well as an increased amount of collagenous tissue between the fibres.

In animal models, the muscle is largely healed after approximately two weeks. It is not known whether the healing in human muscles is substantially different. It is possible that the healing process in human muscles takes longer, as suggested by the clinical symptoms that often last for several weeks (*Almekinders, 1999*).

The majority of muscle lesions heal leaving no specific gross findings, but very often torture victims present with muscular dysfunction in the chronic phases. Typical, but unspecific, findings are: increased muscle tone, restricted stretch range of movement, tender and trigger points, and musculo-tendinous inflammation (*Skylv, 1992*).

Muscle tone

Applying a digital pressure to a muscle, resistance in the tissue opposing deformation occurs. Variations in this resistance are referred to as muscle tone or muscle tension and are described in a continuum from high (hypertone) to low (hypotone). Several causes may lead to deviations in muscle tone, and traditionally these are grouped into three main categories:

1. Organically-determined, e.g. neurological disorder

2. Mechanically-determined, e.g. overload
3. Psychologically-determined, e.g. prolonged stress conditions

Stretch range of movement

A normal muscle may be stretched to its full length with a springy, elastic resistance at the end of range. Stretching of a short, tight muscle evokes pain and – depending on the muscles involved – causes reduced range of movement in the corresponding joint.

A restricted range of movement in muscles may be caused by:

1. Sustained activation of the contractile mechanism of the muscle fibres, e.g. painful trigger points or
2. Reduced elasticity in the passive tissue components, e.g. shortening due to fibrosis (muscle contracture).

Tender and trigger points

A tender point is a hyperirritable spot in a muscle that is painful on compression. Tender points should be distinguished from trigger points, which are hyperirritable spots in a muscle or its fascia that are painful on compression *and* give rise to a characteristic and well-defined pattern of referred pain.

Musculo-tendinous inflammation

Inflammation represents the body's response to tissue injury caused by pressure, friction, repeated load or overload and external trauma. Whatever the nature of the underlying cause, the inflammatory response leads to impaired and painful mobility of the affected part. Inflammatory reactions in the musculo-skeletal system may occur in joints, tendons, tendon and muscle attachments, bursae and the periosteum.

Inflammation of muscle-tendon attachment to bone (teno-periostitis) is clinically characterised by localised tenderness to pressure over the affected attachment and an increase in pain at the site of attachment, when the muscle group concerned is contracted against resistance (isometric testing).

Inflammation of tendons (tendinitis) and bursae (bursitis) is clinically characterised by tenderness, and in the acute phase swelling and crepitus may be present.

Ligaments injuries

Exceeding the normal range of movement in a joint or loading the joint by traction, as in suspension and other types of positional torture, the ligaments may be sprained. An inflammatory response with swelling, pain and joint dysfunction will be present in the acute phase.

1. In a first-degree distortion, the ligaments are sprained without macroscopic rupture, and there will be no mechanical instability in the joint.
2. In a second-degree distortion, there will be a partial macroscopic rupture of the ligaments, leading to a slight mechanical instability in the joint.
3. In a third-degree distortion, the ligaments will be completely ruptured and the joint clearly mechanically unstable.

The healing process in ligaments and tendons is considerably slower than that of muscles. A full recovery with normalisation of strength and function takes months.

Pain and joint dysfunction are very frequent complaints in the chronic phase. At clinical examination, reduced range of movement in peripheral joints, as well as in the spine, is the most typical finding, but various degrees of joint laxity/instability may also be found (*Rasmussen, 1990; Skylv, 1992; Forrest, 2002*). Specific clinical tests may be applied for diagnosing the instability and direction of instability in joints.

Bone injuries

Fractures produce a loss of bone integrity due to the effect of a blunt mechanical force on various vector planes. A direct fracture occurs at the site of impact or at the place at which the force was applied. The location, contour and other characteristics of a fracture reflect the nature and direction of the applied force.

In the acute phase, local swelling, bony deformity, tenderness and loss of function will be typical findings at the clinical examination. In the chronic phase, various degrees of bony deformity, pain at activity and loss of function may be found.

Fractures related to alleged physical torture are reported with a frequency of 13% in a study by Rasmussen (1990), of 27% in a study by Allodi (1985) and of 4% in a study by Randall, Lutz and Quiroga (1985); limb and rib fractures being predominant. Various types of spinal fractures and other lesions, including lesions in intervertebral discs and disc herniation, are likewise reported, but systematic radiodiagnostic studies are lacking (*Aytaçlar & Lök, 2002*).

(See also §183 and §205-210 in the Istanbul Protocol)

POSSIBLE LESIONS AND ASSESSMENT OF THE MUSCULO-SKELETAL SYSTEM FOLLOWING SPECIFIC FORMS OF PHYSICAL TORTURE

The following is not meant to be an exhaustive description of the numerous specific physical torture methods that carries a risk of injury to the musculo-skeletal system. Suspension by the arms and falanga have been selected since they are widely used torture methods that cause chronic disability, and may serve as examples of the variety of lesions that may occur, all of which require special attention at clinical examination.

SUSPENSION BY THE ARMS

There are many types of positional torture, all of which are directed towards the musculo-skeletal system, producing injuries mainly in the soft tissues. Examples include suspension by the limbs, prolonged forced squatting or standing, prolonged back loading positions (the spine being hyperextended or maximally flexed) and restriction of movement during confinement in small cells or cages. Characteristically, these types of torture leave relatively few and unspecific findings, despite subsequent frequently severe, chronic physical disability.

Suspension by the arms, an often-applied torture method, is practised either separately or in combination with other forms of torture, such as beatings and electrical torture. The torture victim is most often tied at the wrists and left hanging for a prolonged period of time by one or both arms. This form of torture is extremely painful and causes an immense overload of the shoulder joint and surrounding soft tissues.

The shoulder is a joint complex comprising four joints: the glenohumeral joint, the sterno-clavicular joint, the acromio-clavicular joint and the “scapula-thoracic” joint. Normal shoulder function requires an optimal coordination between these four joints. The bony anatomy of the glenohumeral joint allows for the greatest possible range of movement found in any joint in the body, sacrificing joint stability for mobility. (Fig. 5)

Additional stabilisation is therefore provided by:

1. Static stabilisers: the glenoid labrum, joint capsule and ligaments (Fig. 6)
2. Dynamic stabilisers: the muscles – in particular the rotator cuff – the deltoid and the long head of the biceps; the “scapula-thoracic” joint; and neuromuscular control ensuring a constant awareness of joint position and joint movement (proprioception).

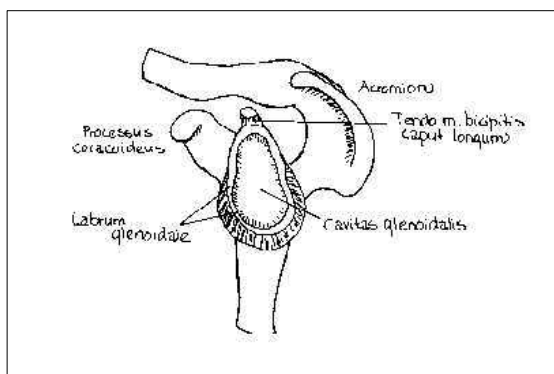


Figure 5. Frontal section through the shoulder joint.

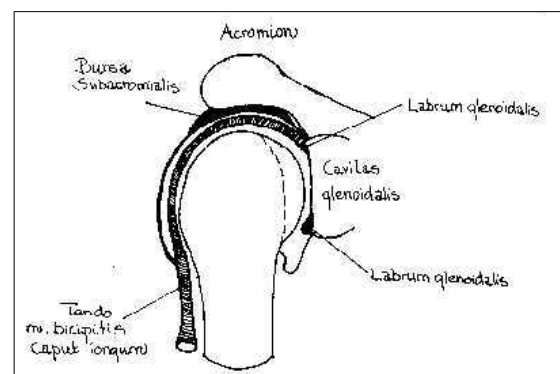


Figure 6. Static stabilisers, labrum glenoidale

During suspension with the arms in forward flexion (Fig. 7), the shoulder joint is maximally flexed and slightly outward rotated. This “closed packed” position provides maximum bony contact between the articular head and the articular socket assisting joint stability.

In *Palestinian hanging* (Fig. 8) the shoulder joint is maximally extended, inward rotated and the entire body weight loading the weak anterior aspect of the shoulder joint placing traction on the brachial plexus. Typically, the lower plexus, and thereafter the middle and the upper plexus fibres if the traction force is severe enough, will be damaged.

If the suspension is of the “crucifixion” type (Fig. 9), the shoulder joints being in abduction, the traction force will primarily be placed on the middle plexus fibres, which are likely to be the first ones damaged (Allden et al., 2001).




Figure 7. Suspension with the arms in forward flexion.

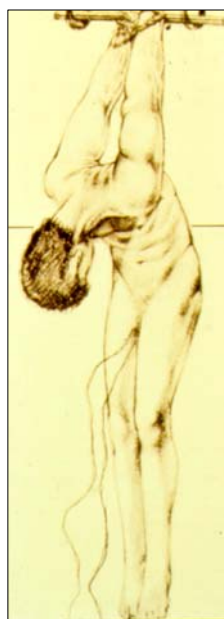

Figure 8. Palestinian Hanging. The shoulder joint maximally extended, and inwards rotated.




Figure 9. Crucifixion. The shoulder joint in abduction.

Acute symptoms and signs

Symptoms in the acute phase are severe pain in the neck and shoulder girdle and in the shoulder joints, and loss of function in the upper extremity. Occasionally, one or both shoulder joints may dislocate during the torture (Forrest, 2002).

Neurological complaints indicative of plexus lesion are frequent: irradiating pain and reduced muscle strength in the upper extremities, accompanied by sensory disturbances, typically in the form of paraesthesia and reduced sensibility. At neurological examination, common findings are reduced muscle strength, most prominent distally, loss/reduction of tendon reflexes and sensory disturbances along the sensory nerve pathways (Allden et al., 2001).

Symptoms and signs in the chronic phase

Many torture victims who have been exposed to suspension by the arms, in particular Palestinian hanging, develop chronic disability with pain, reduced shoulder function and permanent neurological deficit, indicative of partial lesion of the brachial plexus, most often involving sensory modalities. Systematic studies – including radiodiagnostic evaluation of possible lesions in the shoulder joint caused by suspension – are, however, not available, and the pathogenesis of the long-lasting symptoms and shoulder dysfunction are therefore not fully understood. Neurogenic pain due to plexus lesion may, however, play an important role (Thomsen, Eriksen & Smidt-Nielsen, 2000; Moreno & Grodin, 2002).

In the late stages, typical complaints are pain in the neck and shoulder girdle, deep pain in the shoulder joints during activity, especially in connection with overhead movements (abduction, inward rotation) and lifting, reduced range of movements in the shoulder joints, feeling of instability in the shoulder joints or popping, locking sensations on movement.

Neurological symptoms are likewise frequent: irradiating pain, muscle weakness with a feeling of heaviness in the upper extremities and various sensory disturbances, including vasomotor and sudomotor changes.

At clinical examination, most of the findings are unspecific and confined to the soft tissues: typical findings are tender and trigger points in the neck and shoulder girdle, muscular imbalance with musculo-tendinous inflammation in dynamic shoulder stabilisers and shoulder impingement. At joint examination, a reduced range of active movement in the shoulder joint is common. Signs of habitual luxation/subluxation are rare, but upon specific testing, various degrees of instability may be present.

At neurological examination, brachial plexus injury will manifest itself as sensory and motor deficit, depending on the severity of the nerve lesion. Reduced muscle strength, which often is asymmetrical and most pronounced distally as well as reduction/loss of tendon reflexes are signs of motor involvement. Sensory disturbances, which might involve different sensory modalities, are signs of sensory involvement.

Clinical examination

A clinical examination of torture victims submitted to suspension by the arms should include:

1. Examination of shoulder function: passive and active range of movement, joint stability, function of accessory shoulder joints, including scapula function
2. Examination of soft tissues: muscle relief, muscle tone and stretch range, tender and trigger points, tendinitis, shoulder impingement
3. Neurological examination: muscle strength, tendon reflexes and a thorough examination of sensibility, including vibration sensation, positional sensation, two-point discrimination and touch, pain and thermosensation.

(For more information please see §205 – 207 in the Istanbul Protocol)

FALANGA

Acute symptoms and signs

The immediate effect of falanga (repeated applications of blunt trauma to the soles of the feet) is bleeding and oedema in the soft tissues of the feet, as well as severe pain. At clinical examination, changes are also confined to the soft tissues. Swelling of the feet, discoloration of the soles due to haematoma formation and various degrees of skin lesions are typical and diagnostic findings (*Amris & Prip, 2001a; Allden et al., 2001*). Extensive ulcerations and gangrene of toes due to ischaemia have been described, but are not common. Fractures of tarsals, metatarsals and phalanxes are described as occurring occasionally (*Forrest, 2002*).

The acute changes disappear spontaneously within weeks, as the oedema and extravasation of blood resolve, but the induced soft tissue lesions may be permanent.

Symptoms and signs in the chronic phase

The majority of torture victims submitted to falanga complain of pain and impaired walking.

The cardinal symptom is pain in the feet and calves, and two types of pain are usually present:

- A deep, dull cramping pain in the feet, which intensifies with weight bearing and muscle activity spreading up the lower legs
- A superficial burning, stinging pain in the soles, often accompanied by sensory disturbances and frequently also a tendency for the feet to alternate between being hot and cold, suggestive of autonomic instability

Because of the pain, walking is impaired in most falanga victims. Walking speed and walking distance are reduced. Typically, the torture victim is only able to walk a limited distance, during which the pain will increase and make continued muscle activity impossible. At rest, the pain subsides and the victim can resume walking.

Theories explaining the persistent pain and foot dysfunction after falanga

The aetiology and pathogenesis of the persistent pain and disability after falanga is not fully understood. Several theories have been put forward (*Bro-Rasmussen & Rasmussen, 1978; Rasmussen, 1990; Skylv, 1993; Allden et al., 2001; Amris & Prip, 2001b*), and most likely a combination of trauma mechanisms are responsible.

Reduced shock absorbency in the heel pads

The footpads are situated under the weight-bearing bony structures, at which in particular the heel pads act as the first in a series of shock absorbers. The heel pad is normally a firm elastic structure covering the calcaneus. It has a complex internal architecture consisting of closely packed fat cells surrounded by septa of connective tissue, which also contain the nerve and vessel supply to the tissues. Because of its structure, the heel pad is under constant hydraulic pressure and maintains its shape during weight load in the standing position.

After falanga, the heel pad may appear flat and wide, with displacement of the tissues laterally during weight loading. This is observed at inspection from behind, with the torture victim in the standing position. At palpation, the elasticity in the heel pad is reduced and the underlying bony structures are easily felt through the tissues. The pathophysiology of the reduced elasticity in the heel pad is thought to be tearing of the connective tissue septa, leading to deprivation of blood supply and secondary atrophy of fat cells with loss of the shock absorbing ability.

Damaged footpads are not pathognomonic of falanga, but are also described in connection with other conditions unrelated to torture, e.g. lesions in long-distance runners and patient with fractures of the heel bone. It should also be stressed that normal footpads at clinical examination does not rule out exposure to falanga.

Changes in the plantar fascia

The plantar fascia springs from the calcaneus and proceeds to the forefoot. It is tightened during foot of supporting the longitudinal arches of the foot, assisting the foot muscles during walking. Changes in the plantar fascia are present in some torture victims after falanga and are probably due to the repeated direct traumas to this superficial structure. After falanga, the fascia may appear thickened with an uneven surface at palpation, and tenderness may be found throughout the whole length of the fascia, from its spring to the insertion. Disruption of the plantar fascia has been reported, based on the finding of increased passive dorsiflexion in the toes at clinical examination (*Skylv, 1992; Forrest, 2002*).

Closed compartment syndrome

The plantar muscles of the foot are arranged in tight compartments – an anatomical arrangement which makes it possible for a closed compartment syndrome to develop. A closed compartment

syndrome is defined as a painful ischaemic, circulatory disturbance in connection with an increase in pressure and volume inside a well-defined muscle compartment. In the acute form, with a rapidly increasing pressure, e.g. caused by bleeding inside the compartment, the symptoms are alarming and the consequences severe with necrosis of involved tissues if left untreated.

Chronic compartment syndromes may occur as a result of an increase in the muscle bulk and/or a narrowing of the compartment. Clinically, this condition presents itself with pain that intensifies with load and which finally makes continued muscle activity impossible. The pain subsides after a short period of rest, but recurs if muscle activity is resumed – a picture not unlike that seen in impaired walking after falanga.

In a MRI study comparing torture victims exposed to falanga with healthy volunteers, significant thickening of the plantar fascia was found in all victims. Apart from this, morphological changes were present in the fascia, possibly representing scar tissue formation. No signs of detachment of the plantar fascia, closed compartment syndrome or changes in the heel pads were shown in this study (Savnik *et al.*, 2000).

Neurogenic pain

The skin of the soles in the normal foot is apart from the arch area, very thick and firmly tied to the underlying tissues. It is very rich in sensory nerve endings, which register touch and pressure. Peripheral nerve lesion affecting the small nerves of the soles is a very possible consequence of falanga. Neurogenic pain due to nerve lesion is therefore a possible contributing pain mechanism.

Impaired walking

Deviations from the normal gait pattern are very frequent after exposure to falanga. Many torture victims develop a compensatory altered gait with loading of the lateral border (supinating the foot) or loading of the medial border (pronating the foot) to avoid pain at heel strike. The unwinding of the foot is likewise abnormal. Maximal extension and weight loading of the first toe is typically avoided at take-off.

Stride and walking speed are reduced. The gait is broad, stiff and insecure as seen in patients with peripheral neuropathy from other causes. Postural reflexes are elicited from the soles, and, together with the ability to register distribution of pressure, these reflexes are essential for balance and walking. Nerve lesion influencing the proprioception may therefore also contribute to the overall picture.

As a consequence of the altered function of the foot, altered gait and frequently concurrent exposure to other forms of torture involving the lower extremities, a chain reaction of muscular imbalance occurs. The various muscle groups of the lower legs are often painful due to increased muscle tone, tight muscles and fasciae, tender and trigger points, and musculo-tendinous inflammation.

Clinical examination

The clinical examination of torture victims exposed to falanga should include:

1. Inspection and palpation of the soft tissues of the feet: heel pads, plantar fascia, skin
2. Assessment of foot function and gait
3. Examination of soft tissues and joints in the lower extremities
4. Neurological examination

It should be stressed once again that none of the findings at clinical examination in the late phases after falanga are pathognomonic, and that a normal examination of the feet does not rule out the use of this specific torture method.

(See §202 – 204 in the Istanbul Protocol)

NEUROLOGICAL

Acute central nerve neurological problems are associated with severe beating to the head. Of 200 torture victims, 58% had received severe beating to the head and 1/4 of those consequently lost consciousness (*Rasmussen, 1990*). Headaches were the most frequently reported symptom, present in more than 50% of the examined persons. A significant correlation between severe beating to the head and headaches was found. Likewise, there was a significant association with the symptom vertigo present in 20% of the persons.

Violent shaking may produce cerebral injuries identical to those seen in the shaken baby syndrome: cerebral oedema, subdural haematoma and retinal haemorrhages. The first fatal instance of "shaken adult syndrome" was reported by Pounder and Path (1997).

Acute peripheral nerve symptoms are most often reported as a result of handcuffs or tight ropes at the wrist. Lesions of the brachial plexus, especially the lower roots, have been mentioned after suspension, and damage to the long thoracic nerve has been reported after "Palestinian hanging" (*Forrest, 2002*).

Many of the long-lasting symptoms, such as loss of concentration, headaches, memory disturbances and vertigo, could be explained by chronic, organic brain damage (*Abildgaard et al., 1984*) and call for a neurophysiological evaluation in order to evaluate the specific symptoms. It should, however, be borne in mind that many of these symptoms are also related to PTSD. Moreno & Grodin (2002) have published a detailed review article on torture and its neurological sequelae.

(See also §185 in the Istanbul Protocol)

References

- Abildgaard, U., Daugaard, G., Marcussen, H., Jess, P., Petersen, H.D., & Wallach, M. (1984) Chronic organic psycho-syndrome in Greek torture victims. *Danish Medical Bulletin*, 31, 239-242.
- Allden, K., Baykal, T., Iacopino, V., Kirschner, R., Özkalipci, Ö., Peel, M., et al. (Eds.). (2001). *Istanbul Protocol: Manual on the effective investigation and documentation of torture and other cruel, inhuman or degrading treatment or punishment*. Geneva, Switzerland: United Nations. Office of the High Commissioner for Human Rights.
- Allodi, F. (1985). Physical and psychiatric effects of torture: Canadian study. In E. Stover & E. Nightingale (Eds.), *The breaking of bodies and minds: Torture, psychiatric abuses and the health professions* (pp. 66-78). New York: WH Freeman and Co.
- Almekinders, L. C. (1999). Anti-inflammatory treatment of muscular injuries in sport. *Sports Medicine*, 28, 383-388.
- Amris, K., & Prip, K. (2001a). *Falanga Torture. Diagnosis, Assessment and Treatment*. Copenhagen, Denmark: Rehabilitation and Research Centre for Torture Victims (RCT).
- Amris, K., & Prip, K. (2001b). Torturoffer - et liv i smerte [Torture Victim a life in pain]. In U. Fasting & L. Lundorff (Eds.), *Smarter og smertebehandling i klinisk praksis* (pp. 106-129). Copenhagen, Denmark: Munksgaard
- Aytaclar, S., & Lök, V. (2002). Radiodiagnostic approaches in the documentation of torture. In M. Peel, & V. Iacopino (Eds.), *The medical documentation of torture* (pp. 207-220). London: Greenwich Medical Media.
- Bro-Rasmussen, F., & Rasmussen, O. V. (1978). Falanga tortur. *Ugeskrift for Læger*, 140, 3197-3202.
- Edston, E. (1999). Spåren på kroppen kan avslöja tortyr [The traces on the body reveal torture]. *Läkartidningen*, 96, 628-631
- Forrest, D. M. (1999). Examination for the late physical after effects of torture. *Journal of Clinical Forensic Medicine*, 6, 4-13.
- Forrest, D. M. (2002). Examination following specific forms of torture. In M. Peel & V. Iacopino (Eds.), *The medical documentation of torture* (pp. 159-169). London: Greenwich Medical Media.
- Moreno, A., & Grodin, M. A. (2002). Torture and its neurological sequelae. *Spinal Cord*, 40, 213-223.
- Pounder, D. J., & Path, M.R. (1997). Shaken adult syndrome. *American Journal of Forensic Medicine and Pathology*, 18, 321-324.
- Randall, G., Lutz, E., & Quiroga, J. (1985). Long-term physical and psychological sequelae of torture on 44 victims examined in the United States. In E. Stover & E. Nightingale (Eds.) *The breaking of bodies and minds: Torture, psychiatric abuse and the health profession* (pp. 58-66). New York: W H Freeman and Co.
- Rasmussen, O. V. (1990). Medical aspects of torture [Doctoral dissertation, University of Copenhagen, Denmark]. *Danish Medical Bulletin*, 37 (Suppl. 1).
- Savnik, A., Amris, K., Rogind, H., Prip, K., Danneskiold-Samsøe, B., Bojsen-Møller, F., et al. (2000). MRI of the plantar structures of the foot after falanga torture. *European Radiology*, 10, 1655-1659.
- Skylv, G. (1992). Physical sequelae of torture. In M. Basoglu (Ed.), *Torture and its consequences: current treatment approaches* (pp. 38-55). Cambridge: Cambridge University Press.
- Skylv, G. (1993). Falanga: Diagnosis and treatment of late sequelae. *Torture*, 3, 11-15.
- Thomsen, A. B., Eriksen, J., & Smidt-Nielsen, K. (2000). Chronic pain in torture survivors. *Forensic Science International*, 108, 155-163.

PART 3: CARDIOPULMONARY

Acute symptoms include dyspnoea, chest pains, coughing, expectoration and palpitation.

Certain types of torture particularly lead to pulmonary complications.

Beatings to the chest may cause damage to the thoracic wall – including rib fractures – and severely reduce the respiration. Often the consequence is pneumonia.

"Wet submarino" is associated with the potential risk of producing acute lung symptoms, due to aspiration of contaminated water. Harsh prison conditions in humid, cold and dark cells probably often facilitate pneumonia, bronchitis or pulmonary tuberculosis.

Electrical torture may produce cardiac arrest if the current passes through the heart (*Danielsen et al., 1991*).

Long-lasting symptoms in a follow-up study of 22 Greek torture victims (*Petersen et al., 1985*) showed that attacks of tachycardia, palpitations and/or dyspnoea – also combined with anxiety – were found in 6/22, while pain in the thorax – including angina and muscular pain – was found in 5/22, and chronic bronchitis (coughing, exertion dyspnoea) in 8/22 persons. These findings highlight the importance of follow-up studies on torture victims.

Significant ECG changes have been observed in US soldiers held in detention camps in Serbia (*Corovic, Durakovic, Zavalic & Zrinscak, 2000*).

See also §182, §200-201, §213 in the Istanbul Protocol

GASTROINTESTINAL

Acute torture-related symptoms have been described after having a foreign body inserted into the anus. Lesions of the anus and rectum have been described as a consequence of the torture. The lesions give rise to pain and bleeding.

Obstipation is often a secondary symptom to anal pain. On examination of the anus, the following findings should be looked for and documented (*Allden et al., 2001*):

1. Fissures tend to be non-specific findings as they may occur in a number of "normal" situations (constipation, poor hygiene). However, when seen in an acute situation (i.e. within 72 hours), fissures are a more specific finding and may be considered evidence of penetration.
2. Rectal tears with or without bleeding may be noted.
3. Disruption of the rural pattern may manifest as smooth fan-shaped scarring. When these scars are seen out of midline (i.e. not at 12 or 6 o'clock), they may be an indication of penetrating trauma.
4. Skin tags, which may be the result of healing trauma.
5. Purulent discharge from the anus. Cultures should be taken for gonorrhoea and chlamydia in all cases of alleged rectal penetration, regardless of whether a discharge is noted.

Acute gastroduodenal haemorrhage has been reported by a small number of torture victim survivors, and may be explained by the extreme stress.

Acute gastrointestinal symptoms such as abdominal pain, epigastric discomfort, diarrhoea, vomiting, etc., are associated with torture and imprisonment. These symptoms must be considered to be of mixed aetiology, in which mechanisms caused by the stressful situation may be a factor. Insufficient or unappetising food, restriction of liquids and lack of exercise may also be factors related to these gastrointestinal symptoms during imprisonment.

The incidence of gastrointestinal symptoms in the torture victims at the time of medical examination was the same as that of control groups and of the population at large. (*Rasmussen, 1990*).

(See §201 in the Istanbul Protocol)

UROLOGICAL

Severe beating to the kidney region may give rise to the development of haematoma in and/or around the kidney. In many cases, the lesion is accompanied by haematuria. Direct trauma to the urethral mucous membrane, either by beating or electric torture in the urethra, also produces haematuria. Beating at the scrotum may injure testis with subsequent atrophy (*Abildgaard et al., 1984*).

Haemoglobinuria may be mistaken for haematuria. Haemoglobinuria has been described in runners due to "footstrike" hemolysis (*Eichner, 1985*). The same mechanism might explain the "haematuria" in some torture victims. Falanga in particular (beating on the soles of the feet) is somewhat similar to the constant friction of the feet as they strike the ground in runners. Among 34 persons with acute renal failure admitted to hospital after alleged torture in police interrogation centres in Kashmir, only those who were beaten on the soles had evidence of haemoglobinuria (*Malik, Reshi, Najar, Ahmad & Masood, 1995*).

To distinguish haemoglobinuria from haematuria, a centrifuge of the urine should be done. The erythrocyte will precipitate, which will not be the case with haemoglobinuria.

Myoglobinuria occurs as a result of rhabdomyolysis, destruction of the muscle tissue, and may be caused by beating or electrical torture (*Simpson, 1994*). The urine is red or brownish and could be mistaken for blood.

Myoglobinuria is a potentially dangerous condition as it causes damage to the kidneys, with serious risk of acute renal failure (*Malik et al., 1993*).

Dysuria is as a frequent complaint among torture victims, probably caused by torture instruments in some cases and by cold and unhygienic conditions in the rest. Long-lasting bladder or kidney complaints, or both, have not been reported more frequently in torture survivors than in control groups.

(See also §184, §201 in the Istanbul Protocol)

OTORHINOLARYNGOLOGICAL

Beating is the type of torture that carries a high risk of damaging the hearing functions, particularly in the form of "teléfono", in which both ears are beaten simultaneously with the flat of the hand.

"Teléfono" produced immediate, as well as long-lasting, symptoms in the ear (*Rasmussen, 1990*). It produces a shock wave against the eardrum, probably very similar to the one produced by explosions. Kerr (1978) describes the following clinical observations after blast injuries in Belfast:

"Usually sensorineural deafness occurs accompanied by tinnitus. In mild cases this tinnitus and deafness may recover fully in a matter of hours. Severe cases may never recover fully. Perforation of the tympanic membrane is common and occurs in pars tensa which is the lower five-sixths of the tympanic membrane. These perforations vary in appearance and may be linear tears, small holes or subtotal defects. From time to time, there is also damage to the ossicular chain.

Especially high frequency sensorineural deafness occurs with preserved normal hearing for the speech frequencies. The hearing loss may recover up to six months after the explosion."

(See also §178-180 in the Istanbul Protocol)

OPHTHALMOLOGICAL

Acute eye symptoms in torture survivors are conjunctivitis, probably caused by dirty cloths used for blindfolding, which the victims often have to wear for many days and nights on end. Very few long-lasting eye symptoms that are possibly related to torture have been described. Perron-Buscail, Lesueur, Chollet, and Arne (1995) observed opacities in the cornea 10 years after electric torture in the eyes, influencing the vision.

(See also §177 in the Istanbul Protocol)

References

- Abildgaard, U., Daugaard, G., Marcussen, H., Jess, P., Petersen, H.D., & Wallach, M. (1984) Chronic organic psycho-syndrome in Greek torture victims. *Danish Medical Bulletin*, 31, 239-242.
- Allden, K., Baykal, T., Iacopino, V., Kirschner, R., Özkalıpci, Ö., Peel, M., et al. (Eds.). (2001). Istanbul Protocol: Manual on the effective investigation and documentation of torture and other cruel, inhuman or degrading treatment or punishment. Geneva, Switzerland: United Nations. Office of the High Commissioner for Human Rights.
- Corovic, N., Durakovic, Z., Zavalic, M., & Zrinscak, J. (2000). Electrocardiographic changes in ex-prisoners of war released from detention camps. *International Journal of Legal Medicine*, 113, 197-200.
- Danielsen, L., Karlsmark, T., Thomsen, H. K., Thomsen, J. L., & Balding, L.E. (1991). Diagnosis of electrical skin injuries: A review and a description of a case. *American Journal of Forensic Medicine and Pathology*, 12, 222-226.
- Eichner, E. R. (1985). Runner's macrocytosis: A clue to footstrike hemolysis. *American Journal of Medicine*, 78, 321-325.
- Kerr, A.G. (1978). Blast injuries to the ear. *The Practitioner*, 221, 677-82.
- Malik, G. H., Reshi, A. R., Najar, M. S., Ahmad, A., & Masood, T. (1995). Further observations on acute renal failure following torture. *Nephrology, Dialysis, Transplantation*, 10, 198-202.

- Malik, G. H., Sirwal, I. A., Reshi, A. R., Najar, M. S., Tanvir, M., & Altaf, M. (1993). Acute renal failure following physical torture. *Nephron*, 63, 434-437.
- Perron-Buscail, A., Lesueur, L., Chollet, P., & Arne, J.L. (1995). Les brulures electriques corneennes: etude anatomoclinique a propos d'un cas [Electric burns of the cornea. anatomo-clinical study apropos of a case]. *Journal Francais d'Ophthalmologie*, 18, 384-386.
- Petersen, H. D., Abildgaard, U., Daugaard, G., Jess, P. Marcussen, H., & Wallach, M. (1985) Psychological and physical long-term effects of torture. *Scandinavian Journal of Social Medicine*, 13, 89-93.
- Rasmussen, O. V. (1990). Medical aspects of torture [Doctoral dissertation, University of Copenhagen, Denmark]. *Danish Medical Bulletin*, 37 (Suppl. 1).
- Simpson, M. A. (1994). Methods of investigating allegations of electric shock torture: Lessons from South Africa. *Torture*, 4, 27-29

PART 4: GYNAECOLOGICAL EXAMINATION

Throughout history, sexual harassment of women has been a weapon of war and power (*Axelsen & Sveaas, 1994*). In many countries, acts of sexual violence are a common method of torture or inhuman treatment inflicted on women (*Amnesty International, 2001*). It is found that female victims of torture are raped more often than men, although men are also frequently subjected to rape (*Allodi & Stiasny, 1990*). Gender-based and sexual violence is frequently a hidden problem.

Women of any age may be raped, including women over 60 years of age or children (*WHO, 1996*). It must be emphasised that gender-based violence and rape may be only one among many traumas that women have suffered, and that physical consequences are often accompanied by psychological and social consequences.

The impact of gender-based abuse on physical health may be immediate and long-term. However, women who are abused rarely seek medical care for acute trauma (*PATH, 2002*). Barriers for seeking medical care may be reduced by ensuring a sufficient number of female health care workers, and by training health professionals working with refugees and torture victims to recognise victims of sexual violence and rape. It is important to allow the victim sufficient time to disclose the trauma (*Shanks & Schull, 2000*).

Before gynaecological examination, the purpose of the examination should be clear: is it to identify treatment needs or is it to document alleged sexual abuse? In the case of documentation of human rights abuses for legal purposes, it is essential to collect detailed information. It is important that the alleged victim gives her informed consent. When examining victims of sexual violence, every precaution should be taken to minimise retraumatisation. A safe and confidential environment should be ensured. Cultural differences, religion and traditional beliefs may affect the meaning given to experiences, the symptoms expressed, and how people cope with the violent experiences (*Kane, 1995*).

A detailed medical, obstetric and gynaecological history should be taken, including questions on sexual activity, menstruation and contraception. Physical signs after sexual violations and rape depend very much on the interval between the assault and the examination. Immediately after the rape of a woman, semen may be detected. She may have injuries all over her body. There may be bruises and bite marks, on the lips, neck, shoulders, buttocks and breasts. The vulva, vagina, anus and the urethra should be carefully examined and special attention should be paid to the perineum. There may be external signs of perineal tears, with laceration of the margin of the vaginal introitus or anus. Where injuries are gross, fistulae between vagina and the rectum may be seen. The presence and condition of a hymen should be noted. (*Knight, 1991b*).

After electrical torture and/or blows in the genital region, haematuria may be found, due to injuries to the urethra and bladder (*Lunde & Ortmann, 1992*).

Most acute symptoms disappear over time, and it may not be possible to differentiate scars of the perineum from scars after childbirth or scars following a sexually transmitted disease.

Later, women may present themselves with complaints of vaginal bleeding, decreased sexual desire, genital irritation, pain during intercourse and urinary tract infections (*Campbell, 2002*). Sexual torture may leave traces in the musculo-skeletal system, structural injuries, functional disturbances and dysfunctioning of the pelvic joints in women. They often have lumbar pain, and complain of pains in the genitalia, menstrual disturbances and sexual problems (*Arcel, 2002*).

Damage to the genitals is most severe in girls under 15 years of age, and in girls and women who have previously been subjected to female genital mutilation. These girls and women are also at higher risk of contracting sexually transmitted diseases (STDs) or Human Immuno-deficiency Virus (HIV). Health care workers should always consider sexually transmitted diseases after rape. Soldiers, even during peacetime, have STD infection rates two to five times higher than those of civilian populations. The chance of infection is therefore considerable for women who have been raped by soldiers (*Machel, 2000*).

Consequences of pregnancy and delivery, as well as of an unsafe abortion, must be considered. The most frequent complications are incomplete abortion, sepsis, haemorrhage and intra-abdominal injury, such as puncturing or tearing of the uterus (*WHO 1998*).

See §184, §214 –227 and §231 in the Istanbul Protocol

PART 5: EXAMINATION OF CHILDREN ¹

Many cases of torture of children have been documented by human rights organisations, and it is feared that those cases form only the tip of the iceberg (*Amnesty International, 2000*). Yet there is a general disbelief that torture can be perpetrated against children. Torture and sexual abuse of children is widespread, particularly in conflicts dominated by ethnicity (*Southall & Kamran, 1998*). The girl child is doubly susceptible to violence, because of her gender and because of her age (*Chinkin, 1998*).

Children may be secondary torture victims because of the violence or torture perpetrated against one or more of their relatives. They may also be primary victims. Since there are many reports on how children have been subjected to the same torture methods as adults, it may be expected that they present similar physical symptoms as adults. Still, very little is known about the physical consequences of torture that are typical for children. What are the implications of torture for a growing body? How does torture affect the development of a child?

Children should be examined in a way appropriate for their age. Nevertheless, the health professional should realise that for many of the world's children, childhood ends long before they reach the age of eighteen, the age when according to most international standards they become adults. Their stories of the violence suffered by them should be respected and taken seriously. However, they often prefer to stay silent, move away and hide and bury their experiences (*Protacio-Marcelino, de la Cruz, Balanon, Camacho, & Yacat, 2000*).

Children may react to trauma with depression, sleep disturbances, nightmares, anxiety, fears, learning problems, post-traumatic stress disorder and feelings of guilt and self-blame (*Pynoos, Kinzie, & Gordon, 2001*).

After a traumatic event, children may suffer from enuresis and – less frequently – from encopresis (*Kaffman & Elizur, 1983; Simpson, 1993*). Nocturnal enuresis is rather common in children of school age. It occurs more often in boys than in girls. There is a strong association with a family history of bedwetting. Regressive enuresis (occurs after children were previously dry) may be triggered by stressful events. Physical examination and urinalysis are indicated to exclude organic damages, but organic pathology may be found in only a very small number of cases.

Possible differential diagnoses are urinary tract infections (especially girls) and diabetes mellitus. Encopresis is less common than enuresis. It is a problem that in most cases develops as a result of long-standing constipation. It may represent emotional problems. As in the case of enuresis, organic defects are rarely found, but should be excluded.

It would facilitate the recognition of physical consequences of torture if health professionals were familiar with the physical consequences of other non-accidental injuries in children. The shaken infant syndrome has been described as occurring only in very young children, seldom older than two years of age. However, symptoms similar to the shaken infant syndrome have been diagnosed in an adult who had been subjected to shaking during interrogation (*Pounder & Path, 1997*). There has been no systematic study of morbidity amongst the many people who have been submitted to shaking during interrogation.

References

- Allodi, F. & Stiasny, M. B. (1990). Women as torture victims. *Canadian Journal of Psychiatry, 35*, 144-148.
- Amnesty International. (2000). *Hidden scandal, secret shame: Torture and ill-treatment of children*. London: Author.

- Amnesty International. (2001). *Broken bodies, shattered minds: Torture and ill-treatment of women*. London: Author.
- Arcel, L. T. (2002). Torture, cruel, inhuman, and degrading treatment of women: Psychological consequences. *Torture*, 12, 5-19
- Axelsen, E., & Sveaas, N. (1994). Psychotherapeutic understanding of women exposed to sexual violence in political detention. *Nordisk Sexologi*, 12, 1-12
- Campbell, J. (2002). Health consequences of intimate partner violence. *The Lancet*, 359, 1331-1336.
- Chinkin, C. (1998). Torture of the girl-child. In G. Van Bueren (Ed.), *Childhood abused: Protecting children against torture, cruel and inhuman and degrading treatment and punishment* (pp. 81-106). Dartmouth, UK: Ashgate.
- Kaffman, M., & Elizur, E. (1983). Bereavement responses of kibbutz and non-kibbutz children following the death of the father. *Journal of Child Psychology and Psychiatry*, 24, 435-442.
- Kane, S. (1995). *Working with victims of organised violence from different cultures: A Red Cross and Red Crescent Guide*. Geneva, Switzerland: International Federation of Red Cross and Red Crescent Societies.
- Knight, B. (1991b). Deaths associated with sexual offences. In B. Knight, *Forensic Pathology* (pp 385-393). London: Arnold.
- Lunde, I., & Ortmann, J. (1992). Sexual torture and the treatment of its consequences. In M. Basoglu (Ed.), *Torture and its consequences: Current treatment approaches* (pp. 310-329). Cambridge, UK: Cambridge University Press.
- Machel, G. (2000, September). *The impact of armed conflict on children: A critical review of progress made and obstacles encountered in increasing protection for war-affected children*. Report presented at the International Conference on War-Affected Children, Winnipeg, Canada. Retrieved April 2, 2003, from <http://www.waraffectedchildren.gc.ca/machel-en.asp>.
- PATH. Program for Appropriate Technology in Health. (2002). Violence against women: effects on reproductive health [Special issue]. *Outlook*, 20 (1).
- Pounder, D. J, & Path, M.R. (1997). Shaken adult syndrome. *American Journal of Forensic Medicine and Pathology*, 18, 321-324.
- Protacio-Marcelino, E., de la Cruz, T., Balanon, F. A., Camacho, A. Z., & Yacat, Jay A. (2000). *Child abuse in the Philippines: An integrated literature review and annotated bibliography*. Quezon City, Philippines: University of the Philippines. Centre for Integrative and Development Studies.
- Pynoos, R. S., Kinzie, J. D., & Gordon, M. (2001). Children, adolescents, and families exposed to torture and related trauma. In E. Gerrity, T.M. Keane, & F. Tuma (Eds.). *The mental health consequences of torture* (pp. 211-225). New York: Kluwer Academic/Plenum Publishers.
- Shanks, L. & Schull, M. (2000). Rape in war: The humanitarian response. *Canadian Medical Association Journal*, 63, 1152-1156.
- Simpson, M. A. (1993). Bitter waters: Effects on children of the stresses of unrest and oppression. In: J. P. Wilson & B. Raphael (Eds.). *International handbook of traumatic stress syndromes* (pp. 601-624). New York: Plenum Press.
- Southall, D., & Kamran, A. (1998). Protecting children from armed conflict The UN convention needs an enforcing arm. *British Medical Journal*, 316, 1549-1550
- WHO. (1996). *Mental health of refugees* (pp. 123-131) Geneva: Author
- WHO. (1998). *World Health Day, safe motherhood: Address unsafe abortion*. (WHD 98.10). Geneva: Author

Footnotes

- 1) The definition of a 'child' in the UN Convention on the Rights of the Child states "For the purpose of the present Convention, a 'child' means every human being below the age of eighteen years, unless, under the law applicable to the child, majority is attained earlier."

Full list of references

- Abildgaard, U., Daugaard, G., Marcussen, H., Jess, P., Petersen, H.D., & Wallach, M. (1984) Chronic organic psycho-syndrome in Greek torture victims. *Danish Medical Bulletin*, 31, 239-242.
- Allden, K., Baykal, T., Iacopino, V., Kirschner, R., Özkalipci, Ö., Peel, M., et al. (Eds.). (2001). *Istanbul Protocol: Manual on the effective investigation and documentation of torture and other cruel, inhuman or degrading treatment or punishment*. Geneva, Switzerland: United Nations. Office of the High Commissioner for Human Rights.
- Allodi, F. (1985). Physical and psychiatric effects of torture: Canadian study. In E. Stover & E. Nightingale (Eds.), *The breaking of bodies and minds: Torture, psychiatric abuses and the health professions* (pp. 66-78). New York: WH Freeman and Co.
- Allodi, F. & Stiasny, M. B. (1990). Women as torture victims. *Canadian Journal of Psychiatry*, 35, 144-148.
- Almekinders, L. C. (1999). Anti-inflammatory treatment of muscular injuries in sport. *Sports Medicine*, 28, 383-388.
- Amnesty International. (1999). *USA - cruelty in control?: The stun belt and other electro-shock equipment in law enforcement*. (AI Index AMR 51/54/99). London: Author
- Amnesty International. (2000). *Hidden scandal, secret shame: Torture and ill-treatment of children*. London: Author.
- Amnesty International. (2001). *Broken bodies, shattered minds: Torture and ill-treatment of women*. London: Author.
- Amris, K., & Prip, K. (2001a). *Falanga Torture. Diagnosis, Assessment and Treatment*. Copenhagen, Denmark: Rehabilitation and Research Centre for Torture Victims (RCT).
- Amris, K., & Prip, K. (2001b). Torturoffer - et liv i smerte [Torture Victim a life in pain]. In U. Fasting & L. Lundorff (Eds.), *Smerter og smertebehandling i klinisk praksis* (pp. 106-129). Copenhagen, Denmark: Munksgaard.
- Arcel, L. T. (2002). Torture, cruel, inhuman, and degrading treatment of women: Psychological consequences. *Torture*, 12, 5-19
- Axelsen, E., & Sveaas, N. (1994). Psychotherapeutic understanding of women exposed to sexual violence in political detention. *Nordisk Sexologi*, 12, 1-12
- Aytaclar, S., & Lök, V. (2002). Radiodiagnostic approaches in the documentation of torture. In M. Peel, & V. Iacopino (Eds.), *The medical documentation of torture* (pp. 207-220). London: Greenwich Medical Media.
- Bork, K., & Nagel, C. (1997). Long-standing pigmented keloid of the ears induced by electrical torture. *Journal of the American Academy of Dermatology*, 36, 490-491
- Bro-Rasmussen, F., & Rasmussen, O. V. (1978). Falanga tortur. *Ugeskrift for Læger*, 140, 3197-3202.
- Campbell, J. (2002). Health consequences of intimate partner violence. *The Lancet*, 359, 1331-1336.
- Chinkin, C. (1998). Torture of the girl-child. In G. Van Bueren (Ed.), *Childhood abused: Protecting children against torture, cruel and inhuman and degrading treatment and punishment* (pp. 81-106). Dartmouth, UK: Ashgate.
- Cohn, J, Jensen, R, Severin, B, Stadler, H. (1978). Torture in the Argentine, Syria and Zansibar, *Ugeskr Læger*, 140, 3202-3206.
- Corovic, N., Durakovic, Z., Zavalic, M., & Zrinscak, J. (2000). Electrocardiographic changes in ex-prisoners of war released from detention camps. *International Journal of Legal Medicine*, 113, 197-200.
- Danielsen, L (1982). Hudforandringer efter tortur [Skin changes following torture]. *Måndesskrift for praktisk lægegerning*, 193-209.
- Danielsen, L. (1992). Skin changes after torture. *Torture* (Suppl. 1), 27-32
- Danielsen, L. (1995). Hudforandringer efter tortur [Skin changes following torture]. *Sår*, 3, 80-83.

- Danielsen, L. (2002). The examination and investigation of electric shock injuries. In M. Peel, & V. Iacopino (Eds.), *The medical documentation of torture* (pp. 191-205). London: Greenwich Medical Media
- Danielsen, L, Berger, P (1981). Torture sequelae located to the skin. *Acta Dermatovener (Stockh)* 61, 43-46.
- Danielsen, L, Genefke, I.K., Karlsmark, T, Lorenzen, S, Nielsen, K.G., Nielsen, O, Thomsen, HK, Aalund, O (1978). Termiske og elektriske skader i svinehud [Thermic and electric damages in pig skin], 140, 3191-3197.
- Danielsen, L., Gniadecka, M., Thomsen, H. K., Pedersen, F., Strange, S., Nielsen, K. G., Petersen, H.D. (2003). Skin changes following defibrillation. *Forensic Science International*, 134, 134-141.
- Danielsen, L., Karlsmark, T., & Thomsen, H. K. (1997). Diagnosis of skin lesions following electrical torture. *Romanian Journal of Legal Medicine*, 5, 15-20.
- Danielsen, L., Karlsmark, T., Thomsen, H. K., Thomsen, J. L., & Balding, L.E. (1991). Diagnosis of electrical skin injuries: A review and a description of a case. *American Journal of Forensic Medicine and Pathology*, 12, 222-226.
- Danielsen, L, Thomsen, HK, Nielsen, O, Aalund, O, Nielsen, K.G., Karlsmark, T, Genefke, I.K. (1978) Electrical and thermal injuries in pig skin. Evaluated and compared by light microscopy. *Forensic Science International*, 12, 211-225.
- Dyhre-Poulsen, P, Rasmussen, L, Rasmussen, OV (1977). Undersøgelser af et instrument til elektrisk tortur. [Investigation of an instrument of electrical torture]. *Ugeskrift for Læger*, 139, 1054-1056.
- Edston, E. (1999). Spåren på kroppen kan avslöja tortyr [The traces on the body reveal torture]. *Läkartidningen*, 96, 628-631
- Eichner, E. R. (1985). Runner's macrocytosis: A clue to footstrike hemolysis. *American Journal of Medicine*, 78, 321-325.
- European Committee for the Prevention of Torture (CPT). (1998). *Report to the Government of the Netherlands on the visit to the Netherlands Antilles*. Strassbourg, France: Author.
- Forrest, D. M. (1999). Examination for the late physical after effects of torture. *Journal of Clinical Forensic Medicine*, 6, 4-13.
- Forrest, D. M. (2002). Examination following specific forms of torture. In M. Peel & V. Iacopino (Eds.), *The medical documentation of torture* (pp. 159-169). London: Greenwich Medical Media.
- Gniadecka, M., & Danielsen, L. (1995). High-frequency ultrasound for torture-inflicted skin lesions. *Acta Dermato-Venereologica*, 75, 375-376.
- Gordon, E, Mant, A K (1984). Clinical evidence of torture. Examination of a teacher from El Salvador. *Lancet*, 1, 213-214.
- Jacobsen, H. (1997). Electrically induced deposition of metal on the human skin. *Forensic Science International*, 90, 85-92.
- Jakobsson, S. W. (1991). Brett samarbete nödvändigt för diagnostik och behandling av tortyrskador. *Läkartidningen*, 88, 4261-4264.
- Kaffman, M., & Elizur, E. (1983). Bereavement responses of kibbutz and non-kibbutz children following the death of the father. *Journal of Child Psychology and Psychiatry*, 24, 435-442.
- Kane, S. (1995). *Working with victims of organised violence from different cultures: A Red Cross and Red Crescent Guide*. Geneva, Switzerland: International Federation of Red Cross and Red Crescent Societies.
- Karlsmark, T. (1990). Electrically induced dermal changes: A morphological study of porcine skin after transfer of low-moderate amounts of electrical energy. [Doctoral Dissertation, University of Copenhagen, Denmark.] *Danish Medical Bulletin*, 37, 507-520.
- Karlsmark, T, Danielsen, L, Aalund, O, Thomsen, HK, Nielsen, O, Nielsen, KG, Lyon, H, Ammitzbøll, T, Møller, R, Genefke, IK. (1988). Electrically-induced collagen calcification in pig skin. A histopathologic and histochemical study. *Forensic Sci Int*, 39, 163-174

- Karlsmark, T, Thomsen, HK, Danielsen, L, Aalund, O, Nielsen, O, Nielsen, KG, Genefke, IK. (1984) Tracing the use of electrical torture. *American Journal of Forensic Medicine and Pathology*, 5, 333-337.
- Kerr, A.G. (1978). Blast injuries to the ear. *The Practitioner*, 221, 677-82.
- Kjærsgaard, Aa R, Genefke, I K, (1977). Torture in Uruguay and Argentina. *Ugeskrift for Læger*, 139, 1057-1059.
- Knight, B (1991a). The pathology of wounds. In B. Knight, *Forensic Pathology* (pp 123-156). London: Arnold.
- Knight, B. (1991b). Deaths associated with sexual offences. In B. Knight, *Forensic Pathology* (pp 385-393). London: Arnold.
- Lunde, I., & Ortmann, J. (1992). Sexual torture and the treatment of its consequences. In M. Basoglu (Ed.), *Torture and its consequences: Current treatment approaches* (pp. 310-329). Cambridge, UK: Cambridge University Press.
- Machel, G. (2000, September). *The impact of armed conflict on children: A critical review of progress made and obstacles encountered in increasing protection for war-affected children*. Report presented at the International Conference on War-Affected Children, Winnipeg, Canada. Retrieved April 2, 2003, from <http://www.waraffectedchildren.gc.ca/machel-en.asp>.
- Malik, G. H., Reshi, A. R., Najar, M. S., Ahmad, A., & Masood, T. (1995). Further observations on acute renal failure following torture. *Nephrology, Dialysis, Transplantation*, 10, 198-202.
- Malik, G. H., Sirwal, I. A., Reshi, A. R., Najar, M. S., Tanvir, M., & Altaf, M. (1993). Acute renal failure following physical torture. *Nephron*, 63, 434-437.
- Moreno, A., & Grodin, M. A. (2002). Torture and its neurological sequelae. *Spinal Cord*, 40, 213-223.
- Nancke-Krogh, S, (1985). *Kunsten på kroppen [The art on the body]*. Copenhagen.
- PATH. Program for Appropriate Technology in Health. (2002). Violence against women: effects on reproductive health [Special issue]. *Outlook*, 20 (1).
- Perron-Buscail, A., Lesueur, L., Chollet, P., & Arne, J.L. (1995). Les brulures electriques corneennes: etude anatomoclinique a propos d'un cas [Electric burns of the cornea. anatomo-clinical study apropos of a case]. *Journal Francais d'Ophthalmologie*, 18, 384-386.
- Petersen, H. D., Abildgaard, U., Daugaard, G., Jess, P. Marcussen, H., & Wallach, M. (1985) Psychological and physical long-term effects of torture. *Scandinavian Journal of Social Medicine*, 13, 89-93.
- Petersen, H. D., & Rasmussen, O.V. (1992). Medical appraisal of allegations of torture and the involvement of doctors in torture. *Forensic Science International*, 53, 97-116.
- Pounder, D. J, & Path, M.R. (1997). Shaken adult syndrome. *American Journal of Forensic Medicine and Pathology*, 18, 321-324.
- Protacio-Marcelino, E., de la Cruz, T., Balanon, F. A., Camacho, A. Z., & Yacat, Jay A. (2000). *Child abuse in the Philippines: An integrated literature review and annotated bibliography*. Quezon City, Philippines: University of the Philippines. Centre for Integrative and Development Studies.
- Pynoos, R. S., Kinzie, J. D., & Gordon, M. (2001). Children, adolescents, and families exposed to torture and related trauma. In E. Gerrity, T.M. Keane, & F. Tuma (Eds.). *The mental health consequences of torture* (pp. 211-225). New York: Kluwer Academic/Plenum Publishers.
- Randall, G., Lutz, E., & Quiroga, J. (1985). Long-term physical and psychological sequelae of torture on 44 victims examined in the United States. In E. Stover & E. Nightingale (Eds.) *The breaking of bodies and minds: Torture, psychiatric abuse and the health profession* (pp. 58-66). New York: W H Freeman and Co.
- Rasmussen, O. V. (1990). Medical aspects of torture [Doctoral dissertation, University of Copenhagen, Denmark]. *Danish Medical Bulletin*, 37 (Suppl. 1).
- Savnik, A., Amris, K., Rogind, H., Prip, K., Danneskiold-Samsoe, B., Bojsen-Moller, F., et al. (2000). MRI of the plantar structures of the foot after falanga torture. *European Radiology*, 10, 1655-1659.

- Shanks, L. & Schull, M. (2000). Rape in war: The humanitarian response. *Canadian Medical Association Journal*, 63, 1152-1156.
- Simpson, M. A. (1993). Bitter waters: Effects on children of the stresses of unrest and oppression. In: J. P. Wilson & B. Raphael (Eds.). *International handbook of traumatic stress syndromes* (pp. 601-624). New York: Plenum Press.
- Simpson, M. A. (1994). Methods of investigating allegations of electric shock torture: Lessons from South Africa. *Torture*, 4, 27-29
- Skylv, G. (1992). Physical sequelae of torture. In M. Basoglu (Ed.), *Torture and its consequences: current treatment approaches* (pp. 38-55). Cambridge: Cambridge University Press.
- Skylv, G. (1993). Falanga: Diagnosis and treatment of late sequelae. *Torture*, 3, 11-15.
- Southall, D., & Kamran, A. (1998). Protecting children from armed conflict The UN convention needs an enforcing arm. *British Medical Journal*, 316, 1549-1550
- TAT-Group against Torture (2001) Torture in Basque Country, Report 2001. Gipuzkoa, Spain.
- Thomsen, A. B., Eriksen, J., & Smidt-Nielsen, K. (2000). Chronic pain in torture survivors. *Forensic Science International*, 108, 155-163.
- Thomsen, H. K. (1984). *Electrically induced epidermal changes. A morphological study of porcine skin after transfer of low-moderate amounts of electrical energy*. [Doctoral dissertation, University of Copenhagen, Denmark]. Copenhagen, Denmark: FADL.
- Thomsen, H.K, Danielsen, L, Nielsen, O, Aalund, O, Nielsen, K.G., Karlsmark, T, Genefke, I.K Christoffersen, P. (1983). The effect of direct current, sodium hydroxide and hydrochloric acid on pig epidermis. *Acta pathologica.microbiologica immunologica scandinavia, Sect. A*, 91, 307-316.
- WHO. (1996). *Mental health of refugees* (pp. 123-131) Geneva: Author
- WHO. (1998). *World Health Day, safe motherhood: Address unsafe abortion*. (WHD 98.10). Geneva: Author
- Öztop, F., Lök, V., Baykal, T., & Tunca, M. (1994). Signs of electrical torture on the skin. *Human Rights Foundation of Turkey. Treatment and Rehabilitation Centers report*, 11, 97-104.

Legend to figures

Figure 1. Long, straight or curved, linear scars in an asymmetric pattern on the back (Danielsen, 1992). Published with kind permission from Torture.

Figure 2. Symmetrical, atrophic, depigmented, linear changes on the back typical of striae distensae (Danielsen, 1992). Published with kind permission from Torture.

Figure 3. A scar shaped like a boat, placed across the calf with an atrophic centre and a narrow, regular zone of hyperpigmentation in the periphery (Danielsen, 1995). Published with kind permission from Sår.

Figure 4. Venous insufficiency with indistinctly limited hyperpigmentation distally on the lower leg (Danielsen, 1995). Published with kind permission from Sår.

Figure 5. Frontal section through the shoulder joint.

Figure 6. Static stabilisers, labrum glenoidale

Figure 7. Suspension with the arms in forward flexion.

Figure 8. Palestinian Hanging. The shoulder joint maximally extended, and inwards rotated.

Figure 9. Crucifixion. The shoulder joint in abduction.

© International Rehabilitation Council
for Torture Victims (IRCT)

Borgergade 13
P.O. Box 9049
DK-1022 Copenhagen K
DENMARK

Tel: +45 33 76 06 00
Fax: +45 33 76 05 00

<http://www.irct.org>